CHAPTER FOUR

HISTOLOGICAL AND HISTOCHEMICAL OBSERVATIONS AND DISCUSSION ON MUCOSUBSTANCES IN THE ASSOCIATED GLANDS: PROSTATE GLAND AND ALBUMEN GLAND OF *ONCIDIUM VERRACULATUM*

PROSTATE GLAND

A Short Review of Histochemical and Biochemical Work on the Prostate Gland

The structure of the common genital duct is extremely complicated. The male glandular part develops in to the prostate gland which reaches maximum development at the time of copulation; the cavity of this tube is termed the male groove (Runham and Hunter, 1970). Due to the complicated structure of the male duct "Prostate gland", many of the earlier workers seem to have concentrated their attention on the study of the anatomy and histology of this gland (Smith, 1965; Quattrini, 1967a,b; Quattrini and Fondi, 1970). Quattrini and Fondi (1970) have published a series of papers on the structure and the ultrastructure of the molluscan prostate. Some other investigators have studied this gland from the functional point of view, who have attributed the function of spermatophore formation (Lusis, 1961; Smith 1865; Bayne, 1967), the function of nutrition of the sperm (Plesch et al., 1971) and some unknown function at the time of copulation (Lusis, 1961). But there is very scanty literature available on the histochemical and biochemical studies on the mucosubstances and other metabolites of this very important gland, associated with the male reproductive

tract of the hermaphrodite gastropod molluscs. Some histochemical studies showed that the prostate gland of land snail, Ariophanta ligulata, reacted negatively towards the tests for glycogen and acidic mucosubstances[Rangrao (1963)]. Smith (1965) in his histochemical studies, pointed out that this gland probably secretes the material which binds the sperms together in the form of spermatophores.

From the above review of the recent work on the histochemical and biochemical studies of the prostate gland of the snails, it can be seen that, our present knowledge of the chemistry of this gland is far from complete. Roth and Edward (1960), who stated that the thickness of the epithelial lining, the development of the glandular units from the epithelium and the development of the complex folds in the prostate occur most strikingly as sexual maturity is reached.

OBSERVATIONS

I. Histological

The prostate gland of Oncidium verraculatum was an oval yellowish, white coloured compact small gland. It measured about 5 to 6 mm. in length and its size depended on the season and the state of reproductive activity. Histological staining techniques showed a number of polygonal lobules

embedded in the thin connective tissue, which also covered the outer surface of the gland. Each lobule was in the form of a circle of a group of glandular cells arranged radially around a small central lumen or cavity into which these cells poured their secretion. The size of the lumen differed from lobule to lobule. In some cases it was with secretary material packed in it, while in others it was empty. The central lumen was bounded by thin cuboidal epithelial cells. These cells possessed cilia towards the luminal side. Each glandular cell of the lobule was elongated columnar more or less triangular in shape having conspicuous nucleus, situated basally. The glandular cells are concentrated towards the apical portion of the gland. There are two types of glandular cells, one secretory with granular cytoplasm with closely packed innumerable granules and other with no secretory activity. These two types of cells showed no difference in their structure, but their staining reactivity differed towards different histochemical techniques. Secretory cells are concentrated towards apical region and towards the periphery but in the rest of the part they are unevenly distributed. Large lumens are observed containing the secretory material. Since some cells showing a combination of both the types of cells were observed, it appears that one type of cell can be transformed into another.

II. Histochemical

The detailed histochemical investigations on the prostate gland revealed some significant facts about the elaboration of the mucosubstances by the epithelial glandular cells - on the basis of their capacity to elaborate the mucosubstances, the glandular cells which showed differential histochemical reactivities, could be classified into two types - one secretory cells and the other non-secretory cells.

Elaboration of Mucosubstances by the Glandular Epithelial Cells of the Prostate Gland

The histochemical data on some important staining reactions employed in the present investigation of the glandular cells of the prostate gland in the breeding season are recorded in Table No. 3, according to the visually estimated intensity and shade with four plus (++++) representing the strongest activity. The histochemical results requiring further description and consideration are presented here-after along with the interpretations of the histochemical staining reactions.

On the basis of the histochemical reactivities, the glandular epithelial cells could be classified into two types:

Type 1: Secretory Cells

These cells are found to be concentrated in the apical region of the prostate gland. The cytoplasmic granular contents of these cells exhibited intense PAS reactivity which was resistant to prolonged diastase or saliva digestion and it was not abolished by prior phenylhydrazine treatment. These cells exhibit intense alcianophilia both at pH 1.0 and pH 2.5. In the combined sequential staining with AB (pH 1.0, 2.5)-PAS the secretory cells showed intense blue reactivity while pink reactivity is observed on the border. With aldehyde fuchsin these cells exhibit intense purple reactivity. Mild methylation reduced the alcianophilia in the apical glandular part which was not reappeared after saponification but weak alcianophilia reappeared in the scattered secretory cells. In active methylation a complete and irreversible loss of alcianophilia at pH 2.5 was observed. Acid hydrolysis reduced the alcianophilia at pH 2.5, but in the scattered cells it was completely abolished. Further studies on the extinction of the alcianophilia by the addition of graded concentration of Mg^{++} to the staining solution are in progress. The alcianophilic reaction reduced by the addition of 0.1 M Mg^{++} but it was resistant in the apical portion upto 0.5 M Mg^{++}.

All these histochemical reactivities confirm the presence of strong sulfated acidic mucosubstances and the

carboxy mucins in these glandular cells.

Type 2: Non-Secretory Cells

The cytoplasmic contents of these cells exhibited moderate PAS reactivity, which was completely abolished by diastase digestion and by prior phenylhydrazine treatment. These cells reacted negatively with the rest of the histochemical alcianophilic and metachromatic techniques employed. In the combined sequential staining with AB (pH 1.0, 2.5)-PAS, these cells reacted only with PAS giving a pink colouration, there being no trace of blue staining.

The above histochemical reactions indicate that these cells are endowed with a capacity to elaborate only glycogen in them. At a comparative level these cells were more in number than the Type 1 (secretory cells).

DISCUSSION

The investigation of mucosubstances elaborated by the prostate gland of the O.verraculatum, was undertaken with a view to augmenting the understanding of the histochemical nature of the prostate gland. Until recently, the secretion of the prostate gland was supposed to be unidentified polysaccharides. Plesch et al. (1971). The nature of the polysaccharide was not investigated and it was not known in

which cells these polysaccharides are elaborated. The present detailed histochemical investigation confirms the presence of polysaccharides and in addition, shows the nature of these polysaccharides. The polysaccharides elaborated by the secretory cells of this gland are of acidic mucosubstances i.e., both sulfated and carboxy mucins. The present investigation also reveals the cellular site of elaboration of the mucosubstances. The glandular cells can be classified into two distinct types, each having its own mucosubstance content. Thus, there are cells which elaborate only acid mucosubstances and others only glycogen. Thus there is biochemical division of labour at cell level for its secretory function.

Lusis (1961) said that the function of the prostate gland is obscure. Its position and the time in which it begins to secrete, suggested that it is a male accessory organ. The position of its opening at the distal end of the sperm oviduct might indicate that this gland may take part in the copulatory process or in the formation of spermatophores. On the other hand, the nature of its secretion suggests that it may be a source of nutritive material for the spermatozoa. In the support of the above hypothesis, Smith (1965) also remarked that spermatophores might be secreted by the male flask and prostate glands, whereas the sperm nutritive function to the secretory product of prostate gland was supplemented very recently by Plesch et al. (1971). Nanaware (1974) confirms the

Captions to Figures

Plate No. 1

Fig. 1 : T.S. of ovotestis stained with AB (pH 2.5)-PAS to show intense staining in follicular epithelium (GE), moderate in eggs (E) and nurse cells (NC) x 300.

Fig. 2 : T.S. of ovotestis stained with PAS to show intense staining in follicular epithelium (GE), weak in egg (E) and moderate in nurse cells (NC) x 240.

Fig. 3 : T.S. of ovotestis stained with PAS to show intense staining in sperm (S) x 300.

Fig. 4 : T.S. of ovotestis stained with PAS to show intense staining in sperms (S) and moderate in nurse cells (NC) x 300.

Fig. 5 : T.S. of ovotestis stained with PAS showing magnified egg moderately stained x 1350.

Fig. 6 : T.S. of ovotestis stained with PAS showing magnified sperm mass, intensely stained x 1350.

Fig. 7 : T.S. of Hermaphrodite duct stained with AB (pH 2.5)-PAS showing intensely stained sperms (S) and goblet cells in the inner epithelium (EP).
Note - Goblet cells are scattered in the epithelium (EP) x 300.

Fig. 8 : T.S. of Hermaphrodite duct stained with AB (pH 2.5)-PAS showing intensely stained goblet cells in the epithelium (EP) after high magnification x 1350.

Fig. 9 : T.S. of seminal vesicle stained with AB 2.5-PAS showing intensely stained sperm masses (S) and epithelium (EP) x 240.

...

Captions to Figures

Plate No. 2

Fig. 1 : T.S. of albumen gland stained with PAS showing intensely stained globules (GL) x 180.

Fig. 2 : T.S. of albumen gland stained with PAS after diastase digestion.
Note - No effect on PAS reactivity in the globules (GL) x 840.

Fig. 3 : T.S. of prostate gland stained with AB (pH 2.5)-PAS showing intensely stained secretory cells (SC). Non-secretory cells (NC) without staining x 108.

Fig. 4 : T.S. of prostate gland stained with AB (pH 1.0)-PAS showing intensely stained secretory cells (SC) and without any staining are non-secretory cells (NC) x 180.

Fig. 5 : T.S. of prostate gland stained with PAS showing intensely stained secretory cells (SC) x 108.

Fig. 6 : T.S. of prostate gland stained with AB (pH 2.5) showing intensely stained secretory cells (SC) x 108.

...

Captions to Figures

Plate No. 3

Fig. 1 : T.S. of sperm-oviduct stained with AB (pH 1.0) to show intense alcianophilia in goblet cells (GB) and mucocytes (MC) x 112.

Fig. 2 : T.S. of sperm-oviduct stained with AB (pH 2.5)-PAS. Goblet cells in the epithelium (EP) show moderate staining and weak staining in mucocytes (MC) x 300.

Fig. 3 : T.S. of sperm-oviduct stained with AB (pH 2.5) showing weak to poor alcianophilia in epithelial cells (EP) and luminal content (LC) x 80.

Fig. 4 : T.S. of sperm-oviduct showing lumen (L) and Luminal content (LC) stained with PAS. Note - Moderate reactivity in luminal content x 144.

Fig. 5 : T.S. of sperm-oviduct stained with AB (pH 1.0) mucocytes (MC) intensely stained x 90.

Fig. 6 : T.S. of sperm-oviduct stained with AB (pH 1.0)-PAS showing intensely stained goblet cells (GB) x 180.

Fig. 7 : T.S. of Vagina (big) and vas deferens (small) stained with AB (pH 2.5)-PAS showing moderate PAS reactivity in the epithelium (EP) x 180.

Fig. 8 : T.S. of Vagina (big) and vas deferens (small) stained with PAS showing moderate PAS reactivity in the epithelium (EP) x 180.

..

Captions to Figures

Plate No. 4

Fig. 1 : T.S. of spermatheca stained with AB (pH 2.5)-PAS showing moderately stained luminal content (LC) and weakly stained columnar epithelium (EP) x 210.

Fig. 2 : T.S. of spermatheca stained with AB (pH 2.5) showing weak to poor alcianophilia in luminal contents (LC) and columnar epithelium (EP) x 350.

Fig. 3 : T.S. of spermatheca stained with PAS showing moderate to intense reactivity in luminal content (LC) and columnar epithelium (EP) x 180.

Fig. 4: T.S. of spermatheca stained with PAS showing intensely stained columnar epithelium (EP) x 180.

Fig. 5 : T.S. of spermatheca stained with AB (pH 2.5)-PAS showing weakly stained columnar epithelium (EP) x 400.

Fig. 6 : T.S. of spermatheca stained with AB (pH 1.0)-PAS showing moderate staining in the columnar epithelium (EP) x 240.

Fig. 7 : T.S. of Oviduct stained with AB (pH 2.5)-PAS showing luminal content intensely stained (LC) and moderately stained epithelium (EP) x 180.

Fig. 8 : T.S. of Oviduct stained with PAS showing intensely stained luminal content (LC) and moderately stained epithelium (EP) x 180.

..

Captions to Figures

Plate No. 5

Fig. 1 : T.S. of penis stained with PAS showing intensely stained chondroid sheath (CR) and vas deferens (VD) inside the lumen (L) x 80.

Fig. 2 : T.S. of Penis stained with AB (pH 2.5) inner layer of chondroid sheath (CR) showing moderate alcianophilia x 180.

Fig. 3 : T.S. of end sac of penis stained with AB (pH 1.0)-PAS showing intensely stained glands (GL) x 180.

Fig. 4 : T.S. of end sac of penis stained with AB (pH 2.5)-PAS showing intensely stained glands (GL) x 180.

Fig. 5 : T.S. of penial gland stained with AB (pH 2.5)-PAS showing intense reactivity below the inner epithelium (EP) x 120.

Fig. 6 : T.S. of penial gland stained with AB (pH 2.5) showing intense staining below the inner epithelium (EP) x 60.

Fig. 7 : T.S. of end sac of penial gland showing stylet apparatus (PGL) stained with AB (pH 1.0)-PAS. Glands are intensely stained (GL) x 84.

Fig. 8 : T.S. of end sac of penial gland stained with PAS after diastase digestion showing in some glands (GL) weak PAS reactivity x 180.

...

PLATE No. 1

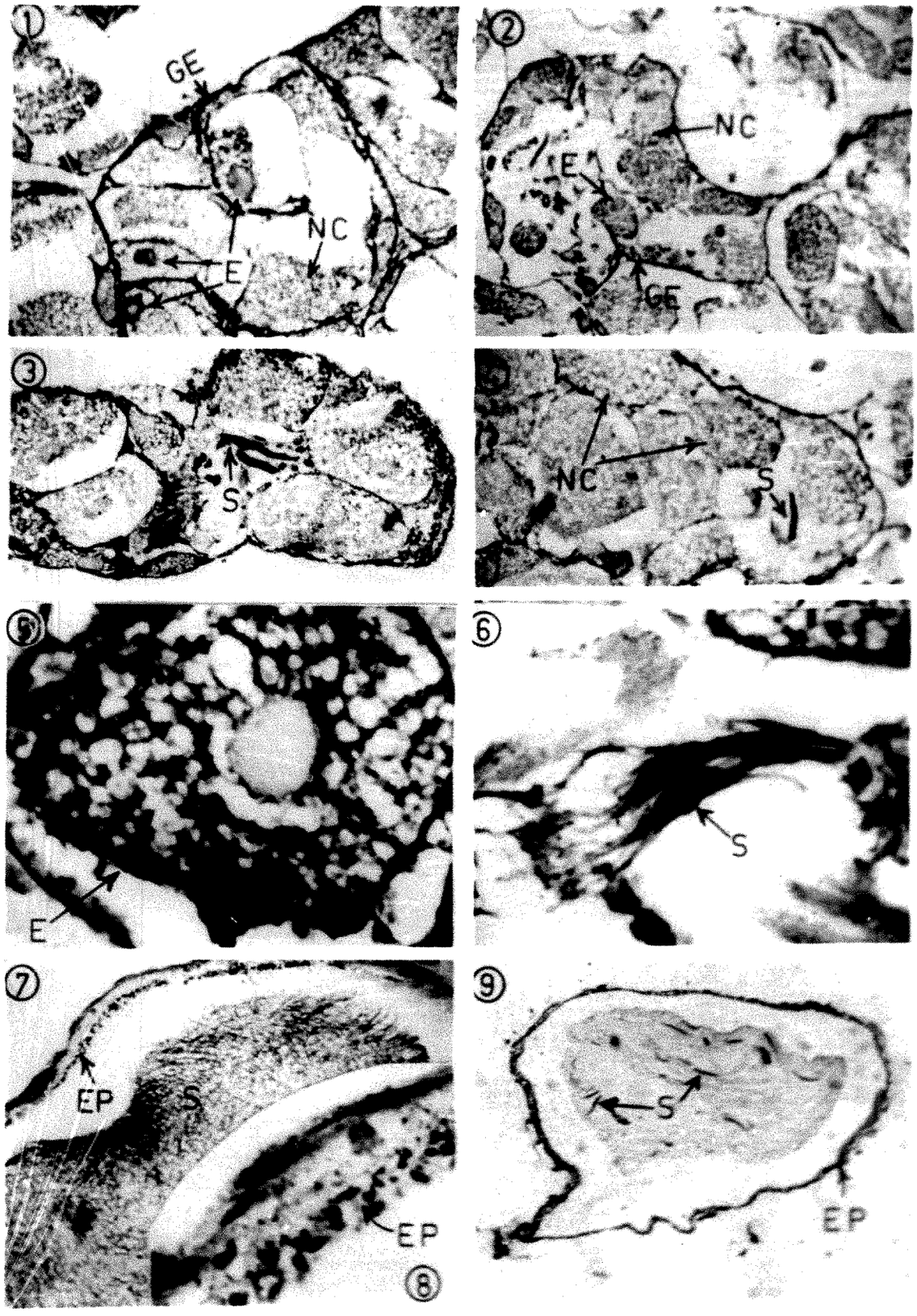

PLATE No. 2

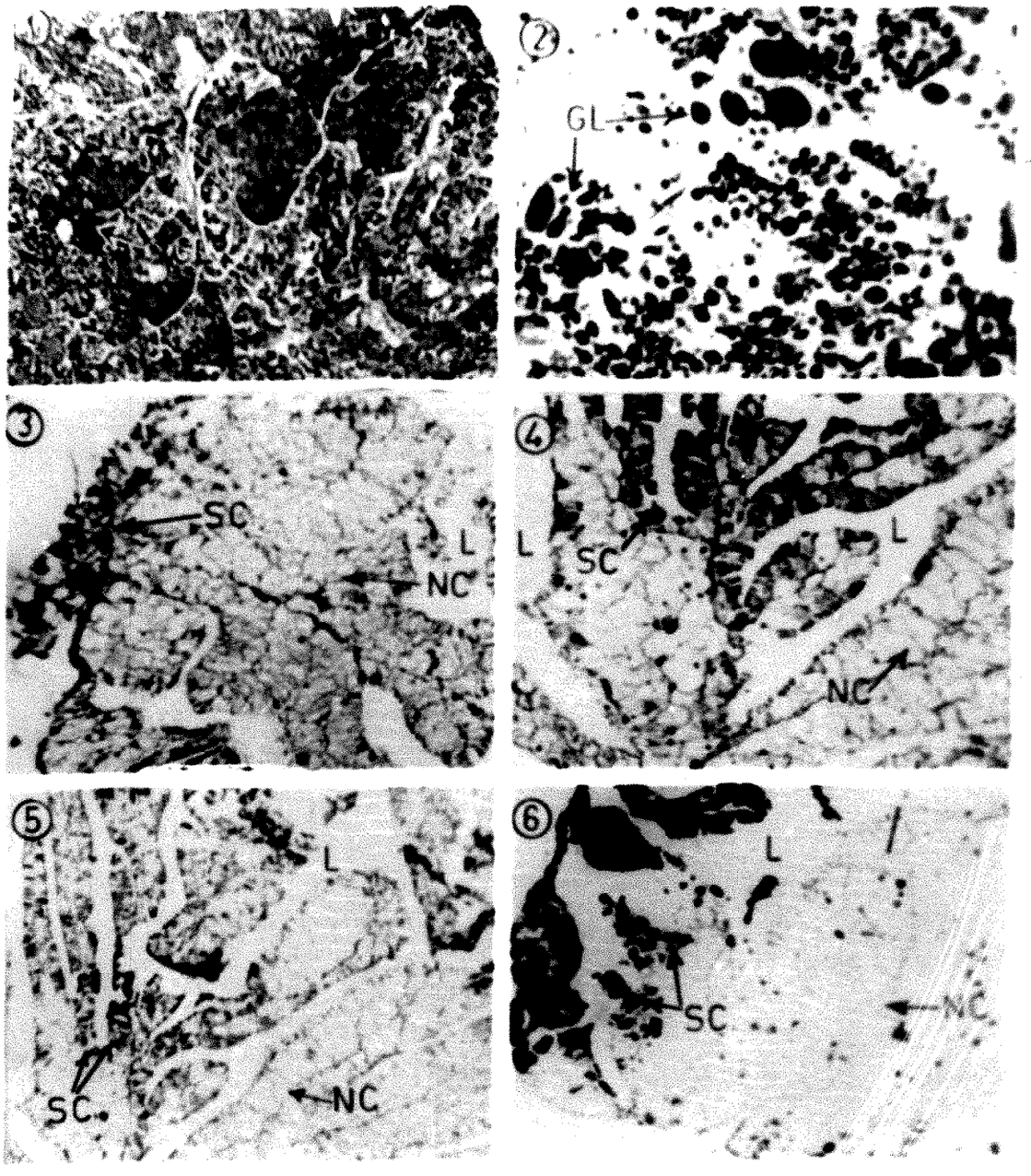

PLATE No. 3

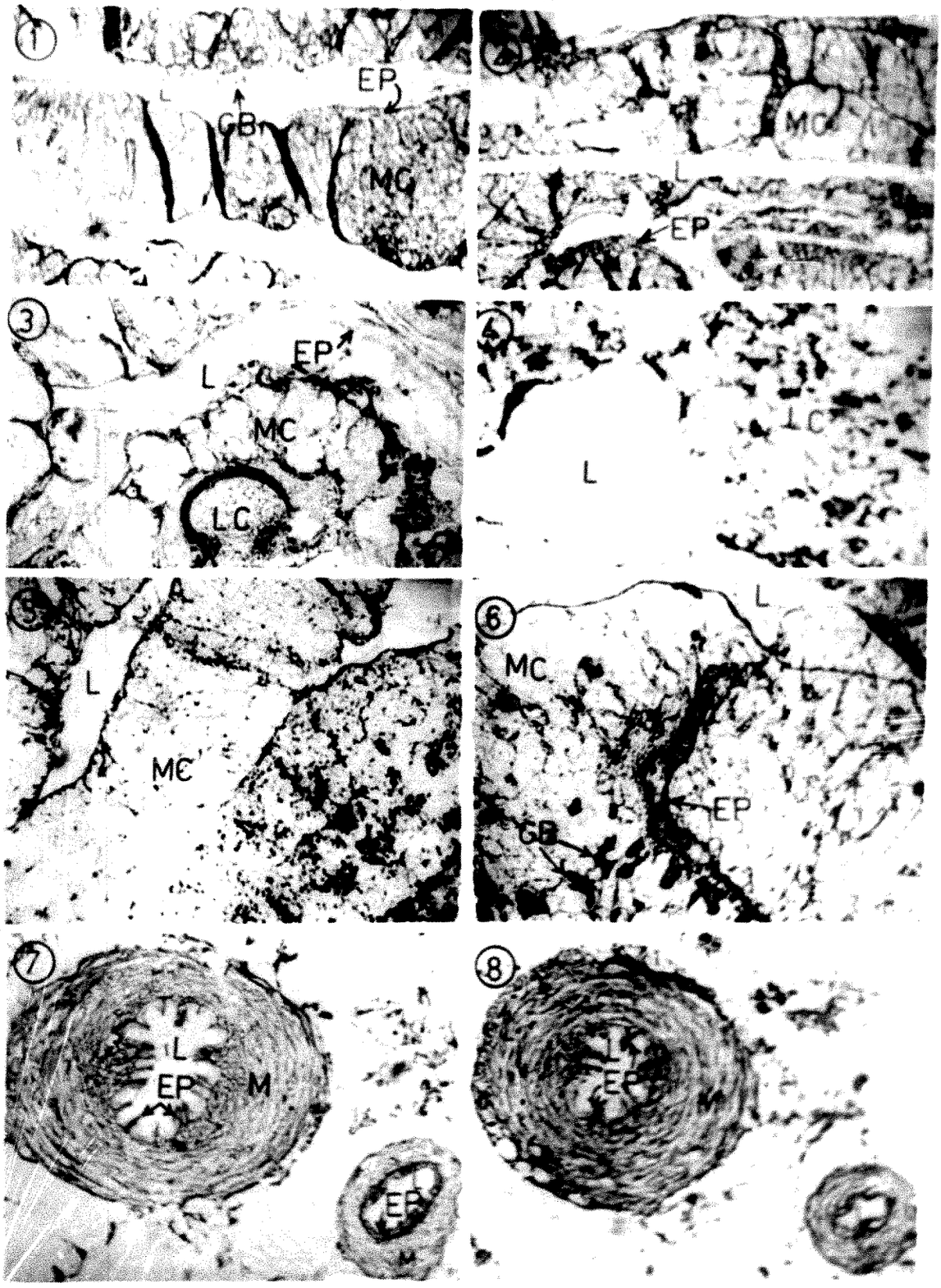

PLATE No. 4

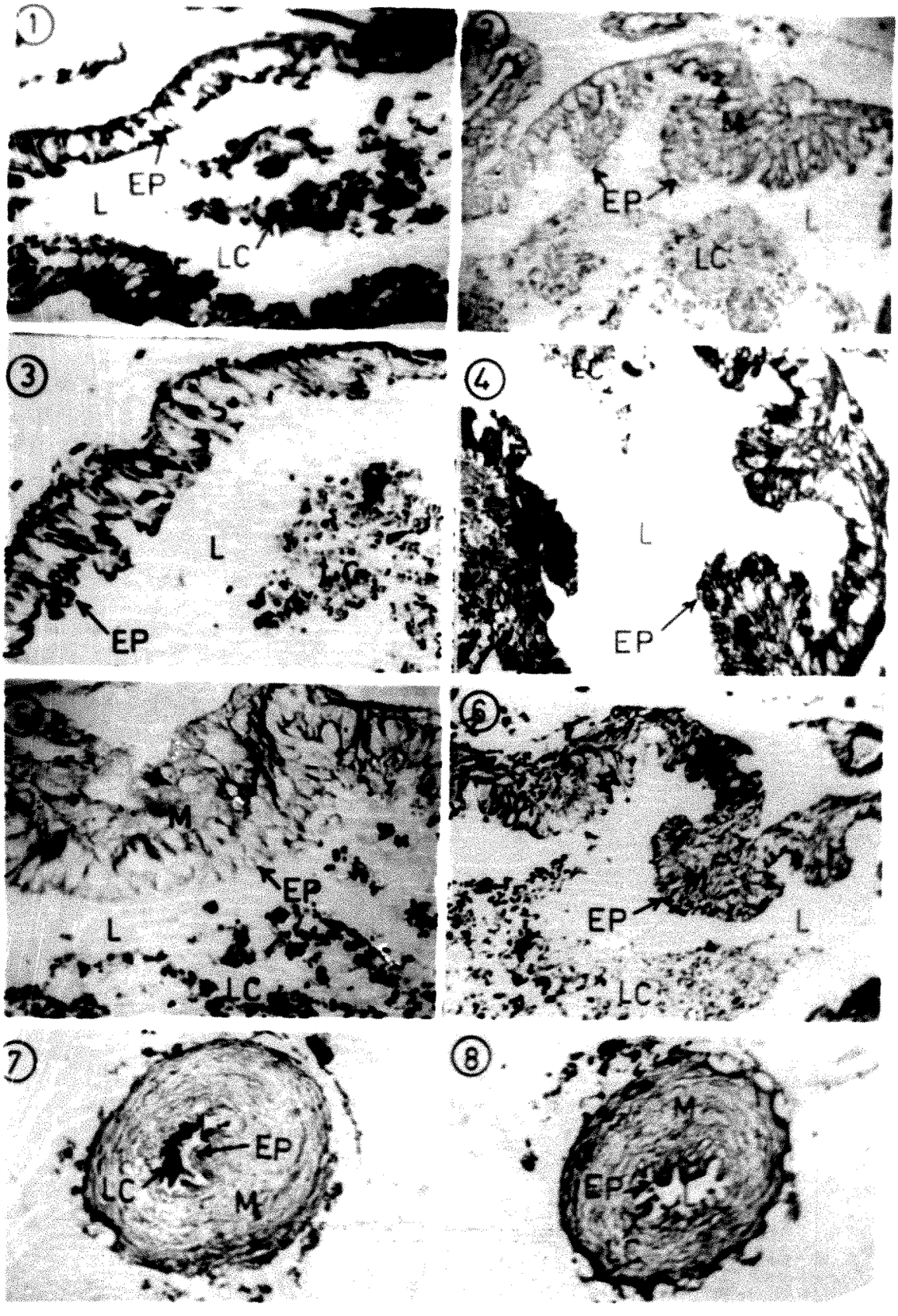
1
EP
L
LC
2
M
EP
L
LC
3
L
LC
EP
4
LC
L
EP
5
M
EP
L
LC
6
M
EP
L
LC
7
EP
LC
M
8
M
EP
LC

PLATE No. 5

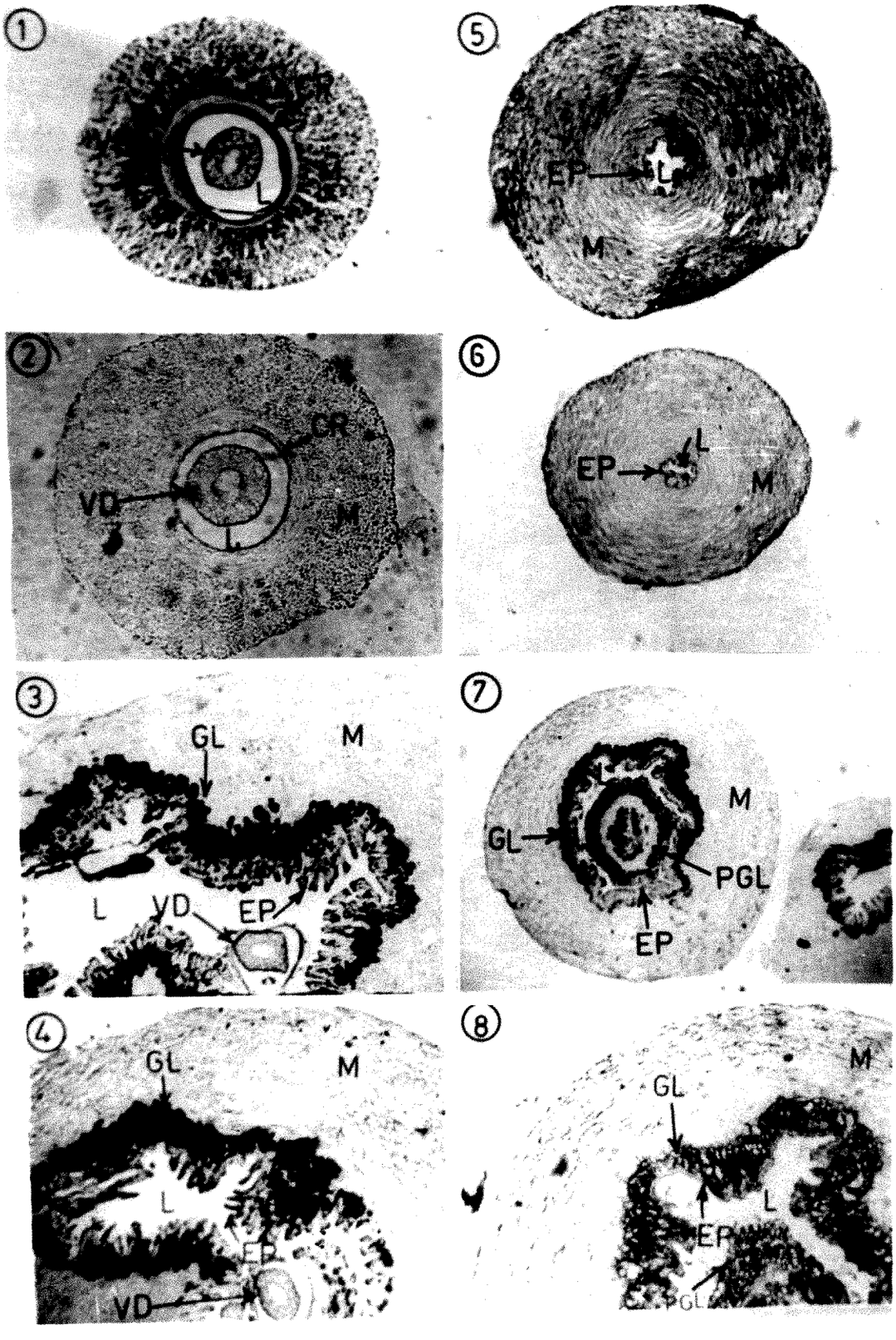
1
CR
L
5
EP
L
M
2
CR
VD
M
L
6
L
EP
M
3
GL
M
L
VD
EP
7
L
M
GL
PGL
EP
4
GL
M
L
EP
VD
8
M
GL
L
EP
PGL

presence of only one type of mucosubstance, i.e., neutral mucin in the secretory cells of the prostate gland of a land pulmonate Semperula maculata. Runham and Hunter (1970) said that during copulation, a large number of sperms pass from the hermaphrodite duct into the male groove, where the sperms are coated with secretions from the prostate gland. Kenny and Inamdar (1959) have attributed lubricating role to these secretions at the time of gliding of sperms along the vas deferens. In all the probability, it seems that the mucosubstance secretion helps in formation of the spermatophores, and provides nutrition for the sperms which were stored for long time in the hermaphrodite duct till the copulation. The fact that there are specialised cells containing large amount of glucose, indicates that this energy material supplies the necessary nutrients to the sperms (Plesch et al., 1971). The other cells seem to secrete phospholipoproteins which may be contributing to the formation of the spermatophores (Ramasubramaniam, 1979).

ALBUMEN GLAND

A Short Review of the Histochemical and Biochemical Work on Albumen Gland

The albumen gland is generally creamy-white, yellow or orange in colour. It varies in size and consistency according to the age of the animal and the season of the year. The gland

consists of a number of variously shaped lobes composed of glandular tubules or follicles lined with columnar cells filled with droplets of non-mucoid secretion (Hyman, 1967). The nature of this non-mucoid droplets has been critically analysed by several investigators who found that it is galactogen, a typical homopolysaccharide which has unusual occurrence in some animal tissues, especially those of molluscs (Baldwin and Bell, 1938; Grainger and Shillitoe, 1952; McMahon et al., 1957; Meenakshi, 1954; Fantin and Vigo, 1968 and Nanaware and Varute, 1974). Due to the important functional significance of galactogen in the reproductive physiology of the pulmonate snails, which is mainly employed in the egg coat formation, the albumen gland and galactogen have been targets of various investigators who have studied this gland from various points of view.

A critical analysis of the recent research works on the albumen gland and chemical studies is described in brief.

Carbohydrates

Except for a few investigators, others have confirmed that the major biochemical constituent in the albumen gland is galactogen. This polysaccharide has been reported in albumen gland of Helix pomatia (Grainger and Shillitoe, 1952), in Ariophanta ligulata (Rangrao, 1963), in Ariolimax

columbianis (Meenakshi and Scheer, 1968), in *Lymnaea stagnalis* (Fantin and Vigo, 1968).

The galactogen elaboration in the albumen gland of gastropod molluscs has been reviewed recently by Goudsmit (1972). Though the galactogen has been extensively studied biochemically (Meenakshi and Scheer, 1969, May and Weinland, 1956a,b) there is scanty literature on the histochemical studies on the galactogen. One of the fundamental reasons why the albumen gland and galactogen have not been extensively investigated histochemically and cytochemically, was the fact that no reliable histochemical criteria were available for the histochemical detection of this typical polysaccharide. Employing certain non-specific histochemical techniques, the galactogen has been studied (Kugler, 1965; Smith, 1965; Duncan, 1958 and Fantin and Vigo, 1968). In very recent years Varute and Nanaware (1972a-d) have reported a confirmatory histochemical technique for galactogen, by means of which it can be histochemically differentiated from other complex polysaccharides. This technique fundamentally depends upon the metachromasia. The development of these new techniques, it is hoped, will facilitate the histochemical studies on the galactogen in the albumen gland of other gastropod molluscs.

OBSERVATIONS

I. Histological

The albumen gland of *Oncidium verraculatum* consisted of a large number of variously shaped lobes, which were widely separated by loose connective tissue. Each lobe consisted of collection of smaller units called as lobules. Each lobule was a circular tube in which single layer of large triangular secretory epithelial cells were peripherally arranged on a basement membrane. The inner border of these cells appeared to be broken and most of the portion towards their inner side was packed with coarse granules at different stages of development (Plate No. 2, Figs. 1 and 2). The secretory product of cells contained in these globules stained red with eosin and sometimes blue with haematoxylin in HE. The secretory cells had eccentric nuclei near their outer borders. There was a lumen of varying size in every tubule.

II. Histochemical

The histochemical data on some important staining reactions employed in the present investigation on the albumen gland are recorded in Table No. 3 according to the visually estimated staining intensity and shade with four plus (++++) representing the strongest activity. The histochemical observations requiring further description and

consideration, are presented hereafter, along with the interpretations of the histochemical staining reactions.

Elaboration of Polysaccharides by the Albumen Gland

The histochemical study on the albumen gland revealed significant fact about the elaboration of unusual polysaccharide-galactogen, by the secretory cells in this gland. This polysaccharide showed very different histochemical reactivities from those of usual animal polysaccharides.

The secretion in the secretory cells of this gland exhibited intense PAS reactivity and PAS reactivity was completely blocked by prior phenylhydrazine treatment, thus indicating presence of neutral polysaccharides in them (Spicer et al., 1967). The PAS reactivity of these granules was not affected by prior diastase or saliva digestion, indicating absence of glycogen in them.

The globules also showed very faint alcianophilia at pH 2.5 but reacted negatively at pH 1.0 with Alcian blue. In the AB (pH 1.0, 2.5)-PAS sequential staining procedures, the globules stained intensely pink.

These globules also showed metachromasia with toludine blue in aqueous solution (0.003%) at pH 3.7, but the metachromasia was lost during alcoholic dehydration. All these

histochemical reactions of the secretory globules resembled those described for galactogen in the albumen glands of other molluscs. The galactogen globules in the albumen gland cells also exhibited metachromasia with dilute solutions (0.02%) of azure A, but it was pH dependent. At lower pH levels viz., 0.5, 1.0, 2.0 and 2.5 no metachromasia was evident even after prolonged staining. However, the granules showed orthochromasia. At pH 3.5 the globules started showing metachromasia but it was moderate. At pH 4.0 the metachromasia was intense. The metachromasia at higher pH levels was evident only in the aqueous solutions, and it was lost during alcoholic dehydration, thus, indicating that the galactogen is capable of exhibiting alcohol-labile metachromasia only at higher pH levels. Metachromasia is also labile to cations, uranyl nitrate, and organic solvents. All these observations were of assistance in differentiation of galactogen metachromasia from other mucosubstances. Thus, the histochemical peculiarities of galactogen are as follows:

1) It exhibits PAS reactivity resistant to prior saliva or diastase digestion, sialidase or hyaluronidase digestion.

2) It exhibits metachromasia with azure A at higher pH levels viz., 3.5 onwards, staining intensity at pH 4.0 reaches the maximum.

3) Metachromatically stained sections were subjected to alcoholic dehydration. Such alcoholic treatment has been shown to abolish the metachromatic staining.

4) Addition of uranyl nitrate (100 meg) in the azure A solution (0.02% adjusted at pH 3.5 to 4.5), no metachromasia of the galactogen was observed.

5) Inorganic ions also suppressed the metachromasia of galactogen.

DISCUSSION

With the help of confirmatory technique recently described by Varute and Nanaware (1972a-d) for detection of galactogen, it is now possible to describe the histochemical characterisation of galactogen in albumen gland of O.verraculatum. Characteristically it exhibits metachromasia at higher pH levels viz., pH 3.0 onwards and it is alcohol-labile. The metachromasia is not succeptible to hyaluronidase and sialidase digestion and also to acid hydrolysis. Galactogen is not endowed with exhibition of any masked metachromasia at low pH levels, since pepsin digestion does not reveal any metachromasia at pH 0.5 to 2.5. The metachromasia is affected by the inorganic ions, but it requires appropriate concentration of the ions, below optimum concentration of the ions it is unaffected.

Some of these metachromatic reactions, when considered in comparison with the metachromasia exhibited by sialomucins and sulfomucins, are found to be characteristic of galactogen. Dilute (0.02%) buffered solution of azure A at pH 2.0 or below stains metachromatically selectively certain strongly acidic sulfated mucosubstances, whereas at pH 4.0 this dye demonstrates additional sulfated mucosubstances with masked azurophilia at lower pH, as well as acidic mucosubstance containing carboxyl groups such as sialomucins or hyaluronic acid (Spicer et al., 1967 and Wislocki et al., 1947).

The present investigation shows that the effects of alcoholic solvents and inorganic cations on the metachromasia induced by these anions are different. Such differences can be made use of in the histochemical detection of such high molecular weight tissue components containing such reactive anionic groups by employing the metachromatic techniques.

Thus, the present investigation on the albumen gland of the marine slug affords an augmentation of the understanding of the histochemical nature of the gland. Until recently (Nanaware, 1974) this highly typical polysaccharide secretion of this gland, galactogen, was studied biochemically and its histochemical characteristics had remained mostly unstudied. The present investigation confirms the finding of galactogen in land pulmonate, Semperula maculata by Nanaware (1974) and

describes in detail the histochemical reactivities of galactogen in albumen gland of marine slug, Oncidium verraculatum, involving metachromasia.

Regarding the functional significance of galactogen in the reproductive physiology of slugs, nothing positive can be said from the present histochemical observations, except for the fact that it is secreted and used up during egg formation as earlier described (Nanaware, 1974). From the available literature, it seems that it is mainly employed in the egg-coat formation.

Besides this functional significance, the present investigation provides a few points for comparison. Earlier investigations showed that in the prosobranchs the habitat and sex decide the site for galactogen synthesis, thus, in terrestrial and fresh water snails galactogen synthesis is associated with the female sex, but in intertidal snails its synthesis is connected with the male sex (Emerson, 1965). Thus, from the available literature it seems that no such relation exists between the elaboration of the galactogen in pulmonate slugs and snails and their habitats; it will be interesting if this chemical moiety be fully explored in relation to different ecological factors, since such results will provide an important basis for taxonomic identification of species.