

CHAPTER FIVE

PAROTID GLAND

Parotid gland is the largest of the three pairs of salivary glands proper in mammals. It consists of pyramidal shaped acinar cells and striated ducts. Myoepithelial cells are closely applied to the basal portion of the cells and reported to have dense cytoplasm with ill defined fibrillar characters. Parotid gland is of serous nature in the number of animals. Leblond, 1950; Bignardi, 1961; Villa and Fava-de-Moraes, 1964 in rat, Gomori, 1954 in dog, Quintarelli and Dellovo, 1969 in opossum, racoon and tapir, showed only neutral mucosubstances in them. On the other hand, histochemically the association of sialic acid and neutral mucosubstances in the parotid gland is reported in sheep and dog (Mogilinaya, 1966); Sloth and Skunk (Quintarelli and Dellovo, 1969) and ox and pig (Munhoz, 1971). Biochemically also this fact is established in the parotid of ox and pig (Aureli et al., 1961b), horse (Aureli et al., 1961a) and marmaset (Sacramento and Miraclia, 1972), dog (Reifel and Travill, 1972). If the cytoarchitecture of the parotid gland is taken into consideration, then it is a serous gland as two third portion of the acinar cells is covered by rough endoplasmic reticulum (Bradfield, 1953; Parks, 1962). Golgi apparatus is well developed, secretory granules are composed of material which is of relatively dense and homogenous (Scott and Pease, 1959). Also there are a number of recent reports describing parotid gland as serous gland (Rutberg, 1961; Hand, 1972; Riva and Riva-Testa,

1973; Ichikawa and Ichikawa, 1977; Herman et al., 1978).

There is vast literature on parotid gland but no where sexual dimorphism of parotid is described. Only the report available on the sexual dimorphism in parotid gland is of Fava-de-Moraes et al. (1966).

#### Material and Methods

Parotid glands were removed from ten adult squirrels, five of them being males and five females, and were fixed within a fraction of time in various fixatives. Samples were fixed in neutral buffered formalin for histology and neutral buffered formalin fixed paraffin wax embedded sections were stained with haematoxylin and eosin. Additional samples were fixed in 2% calcium acetate in 10% formalin for PAS and alcian blue pH 2.5 techniques, whereas 1% calcium chloride in 5% formalin fixed frozen sections were used for the histochemistry of esterase and alkaline phosphatase. For the histochemistry of esterase sections were incubated at 37°C in the incubating medium containing 5-bromoindoxyl acetate as substrate and for alkaline phosphatase histochemistry, sections were incubated at room temperature in the incubating medium containing Naphthol AS-MX phosphoric acid as substrate.

#### Observations

Of the three procedures used, only by haematoxylin-eosin

method acini of parotid were stained but with PAS and Alcian blue pH 2.5 there was no staining activity, parotid gland consisted of acini, intralobular ducts, striated ducts but the number of intralobular duct was very small (Plate No. 4, Figs. 27, 28).

Histochemically demonstrable activity of esterase was intense in the duct system (SD) and also in the acini (AC) of the parotid glands of both male and female squirrel (Plate No. 4, Figs. 29,30).

The strong alkaline phosphatase activity exhibited by myoepithelial cells(↑). The serous acini and ducts of the parotid glands of squirrel showed virtually no enzyme activity. There was no difference in the nature and location of myoepithelial cells in the parotid glands of male and female (Plate No.4, Figs. 31,32).

### Discussion

Parotid glands of squirrel consisted of serous acini as there was no staining reaction with PAS and Alcian blue indicating absence of mucous cells. In addition to serous acini in parotid gland there were well developed striated ducts. There was no difference in the size of serous acini of the parotid glands from male and female. In man, rhesus monkey, dog, cat, rodents and swine these glands are entirely serous

(Leeson, 1967). But Shackelford and Klapper (1962b) have designated parotid glands of dog and cat as belonging to seromucous category on the basis of their carbohydrate histochemistry. Chauncey and Kronman (1964) have reported the presence of scattered mucous acini in the parotid glands of the golden hamster.

In the squirrel parotid glands of both male and female there was intense granular activity for esterase. It was more pronounced in duct system. Weaker esterase activity in acinar than duct is reported by Burstone (1956); Chauncey and Quintarelli (1961); Chessick (1953); Hill and Bourne (1954). Myoepithelial cells were seen in relation to acini. These cells were stained intensely for alkaline phosphatase. Myoepithelial cells are demonstrated by Dewey (1958) in rat parotid gland where these cells are stained for alkaline phosphatase. These cells surrounding acini form an extensive irregular branching network. But there was no difference in these myoepithelial cells from parotid glands of male and female squirrel. Thus, there is no sex difference in the parotid glands either at acinar level or at ductal level and also not in myoepithelial cells distribution and nature. But sex dimorphism in the parotid gland has been reported by Fava-de-Moraes et al. (1966). Critical evaluation of the present observation and literature indicates that there is no

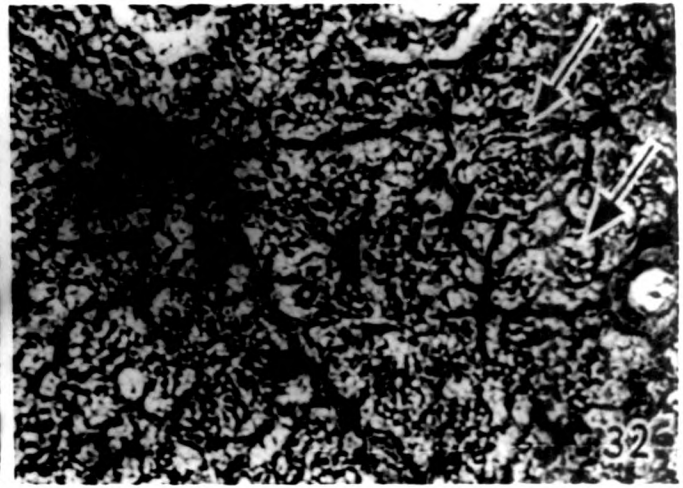
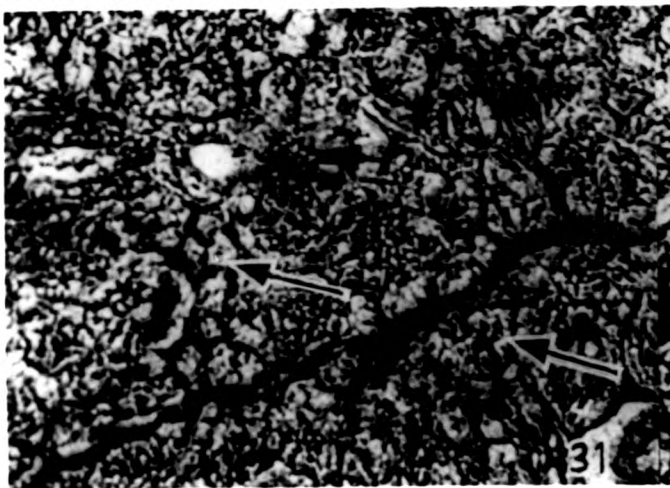
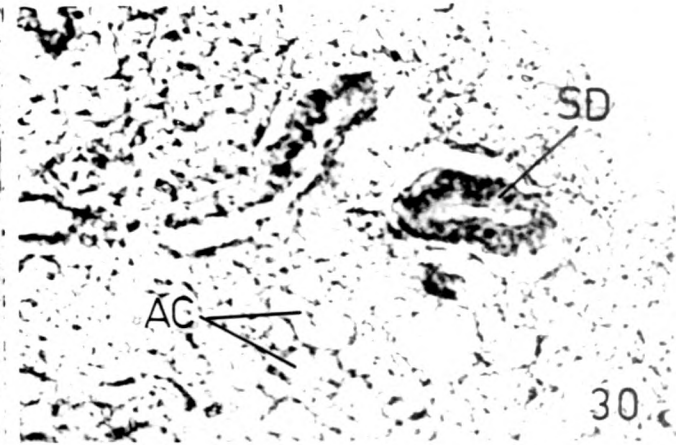
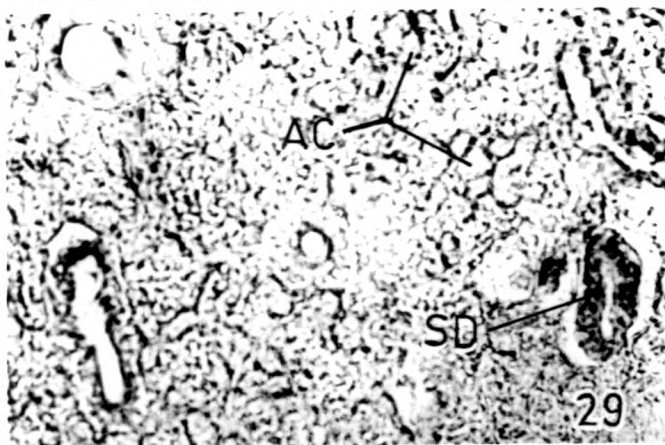
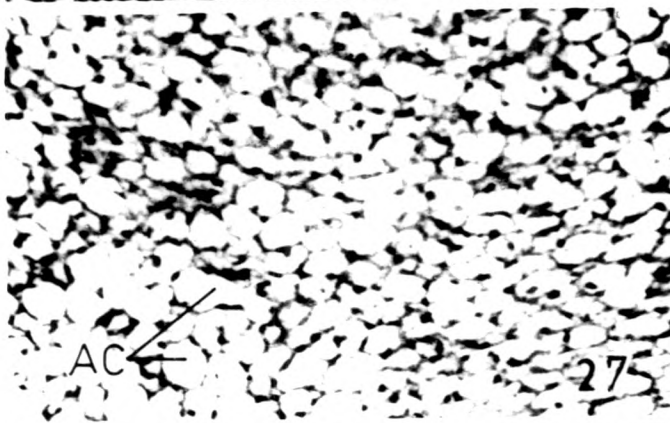

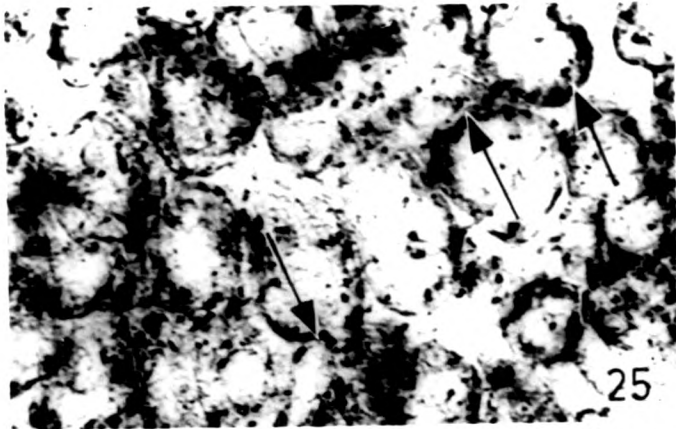
action of either testosterone or estrogen on the parotid gland. Of course, for the conclusion, ablation of ovary and testes and then study of parotid is essential. But hormonal relation of nonspecific type is seen after hypophysectomy in acinar tissue of parotid as after hypophysectomy there is atrophy of acinar tissue (Baker and Abraham, 1955; Baker et al., 1964) and in the hyposectomized animals restoration of normal acinar tissue requires somatotropin, thyroxine and cortisol (Baker, 1958).

Captions to Figures

Plate No. 4, Figs. 25 to 32

- Fig. 25: Sublingual gland of male squirrel stained for alkaline phosphatase. The alkaline phosphatase reaction could be seen at the border of acinar cells which is the site of myoepithelial cells (↑). x 150
- Fig. 26: Sublingual gland of female squirrel stained for alkaline phosphatase. The alkaline phosphatase reaction in photomicrograph could be seen at the border of acinar cells which is the site of myoepithelial cells (↑). x 150
- Fig. 27: Parotid gland of male squirrel stained for H-E showing acini (AC). x 150
- Fig. 28: Parotid gland of female squirrel stained for H-E showing acini (AC). x 150
- Fig. 29: Light photomicrograph of parotid gland of male squirrel stained for esterase. Activity of enzyme esterase is localized in acini (AC) and striated duct (SD). x 150
- Fig. 30: Light photomicrograph of parotid gland of female squirrel stained for esterase. Esterase activity of enzyme esterase localized in acini (AC) and striated duct (SD). x 150
- Fig. 31: Parotid gland of male squirrel stained for alkaline phosphatase. Activity of alkaline phosphatase is seen around the acini, the site of myoepithelial cells (↑).  
x 150
- Fig. 32: Parotid gland of female squirrel stained for alkaline phosphatase. Activity of alkaline phosphatase is seen at the site of myoepithelial cells (↑). x 150

PLATE NO. 4





CHAPTER SIX

SUMMARY AND CONCLUDING REMARKS

A critical analysis of the existing literature shows that sexual dimorphism has been studied in the salivary glands of a number of mammals. But it is confirmed only in the submaxillary glands of rodents and that too only in the rat and mouse (Lacassagne, 1940a; Fekete, 1941, Lacassagne and Causse, 1941; Leblond and Grad, 1948; Grad and Leblond, 1949; Junqueira et al., 1949; Junqueira and Rabinovitch, 1954; Raynaud, 1960, 1964; Gresik, 1966; Caramia, 1966; Andrews and Bullock, 1972; Smith and Frommer, 1972a; Nakamura et al., 1974, Pillai, 1974; Floridi et al., 1976; Marcante, 1977; Doonon et al., 1978). In other rodents like miniature pig (Pinkstaff, 1972, ), White Essex pig (Booth et al., 1973) study of sexual dimorphism is carried out but yet it is not established in these animals, because no further study is carried out so far.

Squirrel is the typical rodent having different habitat from rat and mouse, but study of its salivary gland is not yet carried out. The study of salivary glands of this rodent is essential at least to formate the general nature of the salivary gland of rodents and sexual dimorphism in the rodent salivary glands. This is the reason why the present investigation on sexual dimorphism of salivary glands of squirrel is undertaken.

The following is the brief summary of observations and conclusion drawn in the present investigation:

(A) Submandibular Gland

- 1) Submandibular gland consisted of acini, ducts and myoepithelial cells.
- 2) Acini in the male submandibular glands were of two types - serous and mucous; whereas in the submandibular gland of female they were seromucous and serous. So, in male, acini of submandibular gland were mucous in nature whereas in the female acini of submandibular gland were serous in nature.
- 3) Granular tubules were present in submandibular gland of both male and female, but their number was more in the male submandibular gland than that in the females.
- 4) There was no difference in the nature and distribution of myoepithelial cells.

(B) Sublingual Gland

- 1) Sublingual was mixed gland but more mucous in nature. Secretory elements were mucous acini which were capped by serous demilunes. Ductal system was very poorly developed.
- 2) The mucous acini of male sublingual gland were larger than the female. But these cells are intensely

stained for PAS and <sup>lester</sup>AB pH 2.5 in sublingual gland of female squirrel.

- 3) Careful observations of sublingual gland gave very peculiar observations that mucous acini contained some serous cells in them (↑)  
Number of these serous cells in the mucous acini of sublingual gland of male squirrel was more than the sublingual gland of the female.

#### (C) Parotid Gland

Parotid gland consisted of acini and very few striated ducts. All acini of submandibular glands of male and female are serous in nature. They were not stained for PAS and AB pH 2.5 but intense esterase activity is observed in the acini and striated ducts.

#### Concluding Remarks

Thus, aim and objectives with which the present investigation was undertaken have been successfully fulfilled. The main aim of the present investigation was to study the sexual dimorphism of the salivary glands of squirrel (Funambulus palmarum L.) while concluding the present M.Phil. dissertation on sexual dimorphism the author would like to humbly state that the present work is by no means complete. He is fully aware of his shortcomings. While studying sexual

dimorphism in the salivary glands of squirrel, the author did not consider sex cycle of the squirrel. He did not pay attention to the sexual phase of the female squirrel. For the difficulty of getting squirrels oftenly the author could not carry out any experimental work. The complete report of sexual dimorphism is at histological and histochemical levels and not at biochemical level. And hence the author wishes to carry out further studies in the salivary glands of squirrel.

- (1) Salivary glands further be studied by taking them from various reproductive phases of the female. Male being the continuous breeder, there is no need to consider the reproductive phase.
- (2) Complete histochemistry of mucosubstances in the salivary glands of squirrel should further be carried out.
- (3) Ovariectomy and testectomy followed by hormone replacement therapy should be carried out in both female and male respectively and then their salivary glands should be studied to know hormonal control on the salivary glands of squirrel.
- (4) Biochemical estimations of various mucopolysaccharides and enzymes should be carried out to know quantities of mucosubstances and enzymes in the different glands from male and female.

Thus, the present investigation shows that there are several avenues open for further research.

Some studies are going on in these directions on sexual dimorphism of salivary glands of various mammals. The results of the said studies will be published in the due course of time.